
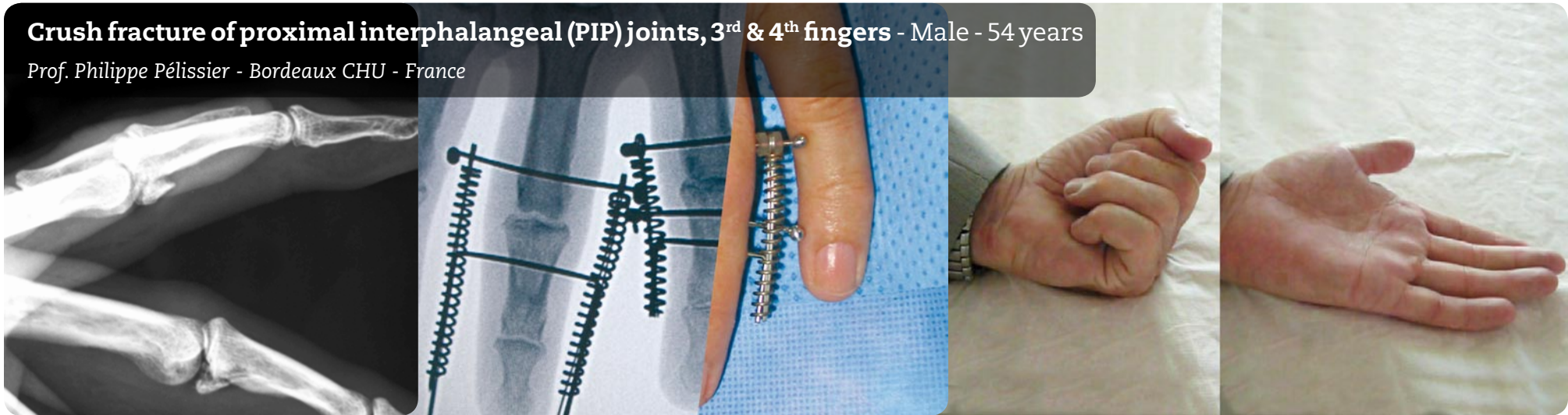
- Adjustable distraction !
- Quick and easy to use
-  0459


Crush fracture of proximal interphalangeal (PIP) joints, 3rd & 4th fingers - Male - 54 years

Prof. Philippe Pélissier - Bordeaux CHU - France



LIGAMENTOTAXOR PRESENTATION

PDF



CLICK HERE

SURGICAL TECHNIQUE

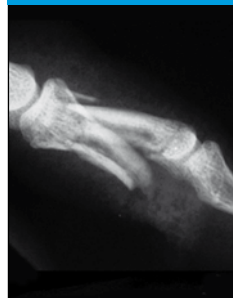PDF / VIDEO



CLICK HERE

CLINICAL CASES

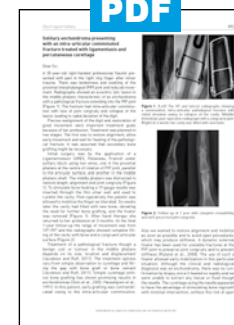PDF / VIDEO



CLICK HERE

PUBLICATIONS

PDF



CLICK HERE

ADMINISTRATIVE DOCUMENTS

PDF



CLICK HERE

PDF



CLICK HERE